JOURNAL OF CURRENT TRENDS IN CLINICAL MEDICINE & LABORATORY BIOCHEMISTRY

Case Report

Partial Open Extrusion Of Talus, Without Malleoli Fracture

[1]Boblee James, [2]H.T.Naveen

ABSTRACT

The talus transfers the body weight onto the hind foot. It is the only bone in the lower limb with no muscular attachment, making it vulnerable to dislocation. Subtalar dislocations are rare, accounting for only 1% to 2% of all dislocations. Given the rarity of talar dislocations. There is no established treatment protocol. We present a case of partial open extrusion of talus.

KEY WORDS: Talus, Dislocation, Subluxation, Ankle joint, Subtalar joint, Talonavicular joint.

History

A 45 years female brought to Sri Lakshmi Narayana Institute of Medical Sciences, Puducherry causality with a history that while working at a construction site, the scaffolding beneath her gave away causing her to fall from a height of 6 feet, as well as causing a tray of mixed concrete to fall over her left ankle as a result of which she sustained an injury to her left ankle. No history of Head injury/ LOC/ Seizures/ENT bleed/chest pain/ abdominal pain/ pelvic pain Patient sustained head injury 7 years ago after, which she developed episodes of seizures, last episodes being five months ago and currently on therapy. On examination, general condition is fair, higher mental functions were intact and vitals were stable. Patient had no evidence of spinal injury. On local examination, an 8x4 cms laceration was present over antero lateral aspect of left ankle. Talus appeared to be subluxated laterally exposing its head. There was gross contamination with soil and organic material in the wound. There were no distal neuro vascular defect. The ankle was splinted and relevant X-rays were taken. The X-rays showed the following, Subluxation of ankle joint, Dislocation of subtalar joint, posterior process of talus, Dislocation of Talo navicular joint.

[1]Professor,
[2]Assistant Professor,
Department of Orthopaedics,
Sri Lakshmi Narayana Institute of Medical Sciences,
Puducherry.

***Corresponding Author**
Dr.Boblee James,
Professor of Orthopaedics,
Sri Lakshmi Narayana Institute of Medical Sciences,
Puducherry-605502, India.
Email id –bobleejames@yahoo.com
Telephone number –09894021718.

MRI of left ankle was taken which showed, medial compartment injury Left ankle with subchondral fracture in postero medial aspect of talus and disruption of medial ligament complex band.

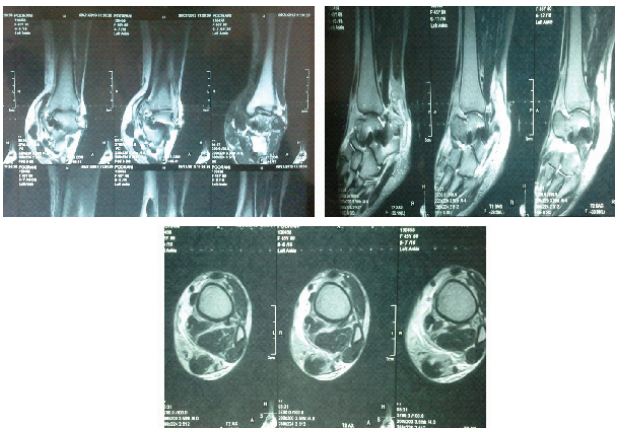

Treatment

Wound debridement , Open reduction and stabilization with trans articular K-wire fixation. Intra-op wound was extended around 5cm anteriorly towards second web space of foot to get good exposure of the joint. Lot of sand, organic material contaminants were found, Interosseous talo-fibular ligament was intact. Communited of sustantalucum tali and fracture of posterior process of talus was seen. Deltoid ligament was torn and FHL tendon was displaced from its sulcus. Wound lavage with 5liters of saline done. The talus was reduced after giving traction on the calcaneum. The reduction was checked with the C-arm, k wire was passed from the calcaneum through the talus into the tibia. Mild subluxation of the talo navicular joint was present which was present on imaging the other ankle.

Intra op

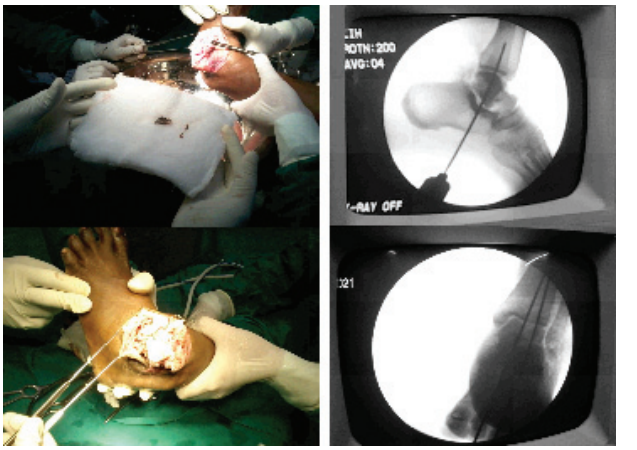

Post op

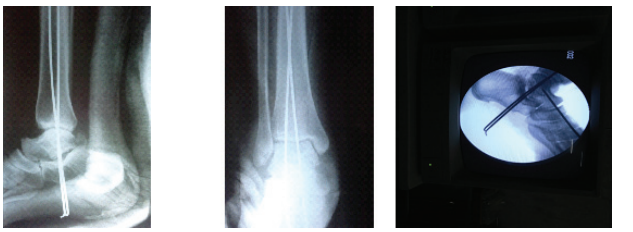

Discussion

The talus transfers the body weight onto the hind foot. It is the only bone in the lower limb with no muscular attachment, making it vulnerable to dislocation [1]. Subtalar dislocations are rare, accounting for only 1% to 2% of all dislocations [2]. Compound injuries account for 54% of all cases reported [3]. Anterolateral dislocations are more common cause. High-energy force, such as a fall from a height or a motor vehicle accident is common cause. Disruption of the vascular supply and contamination may lead

to infection and avascular necrosis, the most common complications affecting the outcome. Given the rarity of talar dislocations, there is no established treatment protocol Some authors recommend primary talectomy with tibiocalcaneal fusion, even in closed injuries [4]. Palomo-Traver suggested reduction except in cases with gross contamination or complete extrusion [5]. Closed or open reduction has been mentioned as the treatment method of choice.

References

1) Wagner R, Blattert TR, Weckbach A. 2004. Talar dislocations. Injury, 35:36 - 45.

2) Perugia D, Basile A, Massoni C, Gumina S, Rossi F, Ferretti A. 2002. Conservative treatment of subtalar dislocations. Int Orthop, 26: 56 - 60.

3) Hiraizumi Y, Hara T, Takahashi M. 1992. Open total dislocation of the talus with extrusion (missing talus): report of two cases. Foot Ankle, 13: 473 - 477.

4) Detenbeck LC, Kelly PJ. 1969. Total dislocation of the talus. J Bone Joint Surg , 51-A: 283-288.

5) Palomo-Traver JM, Cruz-Renovell E, Granell-Beltran V. 1997. Open total talus dislocation : Case report and review of the literature. J Orthop Trauma, 11: 45 - 49.